


**PATIENT**

Rookie Myers

**PRESENTING CLINICAL SIGNS**

 History: Coughing more when playing outside and also vomits occasionally. Has been on Metacam and Gabapentin for arthritis. HR 136, RR panting. Obese. No heart murmur.  
 -Radiographs: Enlarged heart on rads VHS 12.8.

**SPECIES**

Canine

**ECHOCARDIOGRAM FINDINGS**

2D, m-mode, color flow and doppler imaging is available. Normal mitral valve leaflets with no prolapse into the left atrial lumen. Trace mitral regurgitation with no left atrial dilation. Normal LV diameter with adequate myocardial function. The tricuspid valve appears normal with trace tricuspid regurgitation. Normal right atrial and ventricular diameter and morphology indicating no overt evidence of pulmonary arterial hypertension. The pulmonic and aortic valves are normal in morphology and mobility. Normal pulmonic and aortic outflow velocities with laminar flow. No obvious aortic or pulmonic insufficiency. No pericardial or pleural effusion noted. No obvious cardiac masses.

**BREED**

Bulldog

**SEX**

Male Intact

**AGE**

12 years

**CARDIAC CHART**
**WEIGHT**

50.9lbs

CANINE CARDIAC PARAMETERS	MR VMAX (m/s)	TR VMAX (m/s)	LA/AO (Boon method)	LA/AO (Heart Base; Swe)	FS (%)	EF (%)	EPSS (cm)
<b>NORMAL PARAMETER</b>	4.5-5.5	<2.7	1.3	<1.6	28-40	40-100	<0.6
<b>PATIENT</b>	NA	NA	1.3	1.2	43	60	NM
CANINE CARDIAC PARAMETERS	HR (BPM)	AV VMAX (m/s)	PV MAX (m/s)	BODY WEIGHT (kg)	LA 2D short axis Base view (cm)	LVIDd Avg; 2D and m-mode short axis (cm)	LVIDs Avg; 2D and m-mode short axis (cm)
<b>NORMAL PARAMETER</b>	50-100	0.7-1.7	0.7-1.6	BELOW	BELOW	BELOW	BELOW
<b>PATIENT</b>	120	1.3	1.6	23.1	2.2	4.5	3.0
*Normal chamber parameters expressed as a mean value (SD)				3	1.27 (5.3)	2.46 (2.46)	1.36 (5.5)
<b>BODY WEIGHT DEPENDENT PARAMETERS</b>				5	1.40 (4.5)	2.74 (5.2)	1.60 (4.7)
<i>*Note: All measurements based upon multi-modal images and methods. An average value is reported.</i>				10	1.50 (3.8)	3.27 (3.5)	2.06 (3.1)
				15	1.83 (2.0)	3.71 (2.4)	2.43 (2.1)
				20	2.02 (1.9)	4.14 (2.2)	2.80 (2.0)
				25	2.18 (2.4)	4.48 (2.9)	3.10 (2.5)
				30	2.33 (3.3)	4.83 (3.9)	3.39 (3.4)
				35	2.48 (4.3)	5.17 (5.0)	3.69 (4.5)
				40	2.62 (5.2)	5.48 (6.1)	3.96 (5.4)
				50	2.88 (7.1)	6.07 (8.3)	4.46 (7.4)

**INTERPRETED BY**

 Maggie Machen Lamy,  
 DVM DACVIM  
 (Cardiology)

**IMAGING PERFORMED BY**

Crystal Hill, RVT

**HOSPITAL NAME**

 Queensway Animal  
 Hospital

**REFERRING VET**

Dr. Moore

**INTERPRETATION OF THE FINDINGS & FURTHER RECOMMENDATIONS**

 Overtly normal cardiac dimensions and function, with no obvious dysfunction or dilation of the left heart. Trace MR and TR may suggest early valve disease and follow up is advised should a murmur be ausculted in the future. No other significant valvular leaks are visualized, and no evidence of pulmonary hypertension. **It is worth noting that visualization is limited in this study due to signalment/body type. Advanced thoracic evaluation may be warranted depending on CXR evaluation/Radiologist review. This includes referral to a local Cardiologist, a thoracic CT scan, etc. depending on clinical suspicion.**
**INVOICE**

30475

**DATE**

4/27/23



### PATIENT

Rookie Myers

### SPECIES

Canine

### BREED

Bulldog

### SEX

Male Intact

### AGE

12 years

### WEIGHT

50.9lbs

### INTERPRETED BY

Maggie Machen Lamy,  
DVM DACVIM  
(Cardiology)

### IMAGING PERFORMED BY

Crystal Hill, RVT

### HOSPITAL NAME

Queensway Animal  
Hospital

### REFERRING VET

Dr. Moore

### INVOICE

30475

### DATE

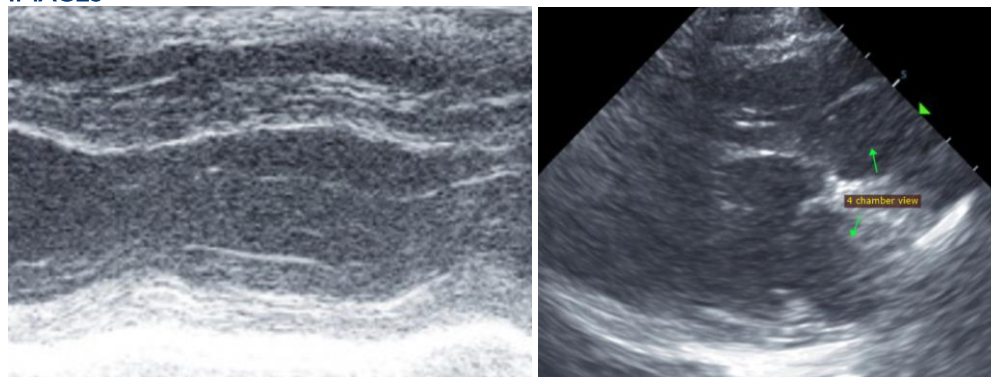
4/27/23

No cardiac medications are indicated at this time as the cough appears non-cardiac in origin. Continued work up for infectious/inflammatory respiratory causes is recommended. Options include Baytril or similar antibiotic, anti-inflammatory prednisone, aggressive hydrocodone, etc. If refractory, may consider TTW/BAL for further information.

Monitor for development of a heart murmur, cough, labored breathing, exercise intolerance or collapse episodes.

Chronic respiratory issues can lead to pulmonary hypertension if poorly controlled and a recheck echocardiogram is recommended should any exertional syncope/dyspnea occur, or a murmur be noted in the future.

### IMAGES



The information and recommendations provided are based on the images presented by the referring veterinarian. No evaluation can be communicated regarding pathology that was not visible in the image/video clips provided.

Thank you for this referral. This report was generated using transcription software, and minor dictation errors may be present. If the clinical or image interpretation does not parallel your findings or if I can be of any further assistance, please contact me.

**Maggie Machen Lamy, DVM**  
Diplomate of the American College of Veterinary Internal Medicine (Cardiology)  
info@sonopath.com